

# Upper Respiratory Tract Tuberculosis: Our Experience Of Three Cases and Review Of Article

E Tas, E Sahin, S Vural, H Turkoz, A Gursel

## Citation

E Tas, E Sahin, S Vural, H Turkoz, A Gursel. *Upper Respiratory Tract Tuberculosis: Our Experience Of Three Cases and Review Of Article*. The Internet Journal of Otorhinolaryngology. 2006 Volume 6 Number 1.

## Abstract

**Objective:** Two cases of nasopharyngeal and one case of laryngeal tuberculosis were analyzed. The clinical and pathological features are discussed.

**Patients And Methods:** We conducted a retrospective study from 2001 to 2004 with analysis of tuberculosis by histopathologic investigations.

**Results:** Tuberculosis of the nasopharynx and larynx is uncommon and may mimic malignant disease. The cases presented were diagnosed by clinical symptoms, histologic appearance, and their response to medication. Finally the diagnosis is proved by growing *Mycobacterium Tuberculosis* on Lowenstein-Jensen culture.

**Conclusion:** It is important to consider tuberculosis in the differential diagnosis of laryngeal and nasopharyngeal lesions, and the histopathologic investigation is the definitive test in differential diagnosis with carcinoma. The response of upper respiratory tract tuberculosis to antimycobacterial therapy is very good.

This work was done in Bakirkoy Dr. Sadi Konuk Education and Research Hospital Otorhinolaryngology Department.

## INTRODUCTION

Tuberculosis is regarded as the most common communicable disease worldwide (1). It used to be a common disease in the upper respiratory tract before the introduction of antituberculosis therapy, but nowadays it is a rare condition even in endemic tuberculosis areas (2).

The most common presentation of nasopharyngeal tuberculosis is; cervical lymphadenopathy with nasopharyngeal mass or mucosal irregularity followed by nasal discharge or obstruction. Clinically it appears to resemble cancer, presenting a nasopharyngeal mass with concomitant enlarged neck lymph node.

Tuberculosis of the larynx involves mainly the vocal cords and the ventricular band, and is associated with pulmonary tuberculosis in 80% of cases. As it is usually seen in smoking male patients, accompanied by hoarseness and a laryngeal mass, it may be confused with laryngeal malignancies.

In this article we report two cases of nasopharyngeal and one case of laryngeal tuberculosis that came to our clinic between the years 2001-2004. The first case is a 14 year-old girl presented primary tuberculosis of nasopharynx with right cervical mass which simulated a malignancy, but found to be tuberculosis histologically and serologically. Our second case is a 20 year-old male, complaining of nasal obstruction, snoring and neck mass. His final diagnosis was primary nasopharyngeal tuberculosis. The third case is a 53-year-old male that presented as a laryngeal mass resembling carcinoma. However the histopathologic and serologic examinations revealed the diagnosis as tuberculosis. It is important to consider tuberculosis in the differential diagnosis of nasopharyngeal and laryngeal lesions, and take biopsies for histological and bacteriological studies.

## PATIENTS AND METHODS

Three patients with head and neck tuberculosis, two nasopharyngeal and one laryngeal, were identified during the years 2001-2004, and review of article was made. An initial diagnosis of tuberculosis, made based on clinical suspicion, histopathological evaluation, their response to medication,

and confirmed by growing *Mycobacterium Tuberculosis* on Lowenstein- Jensen culture.

### CASE 1

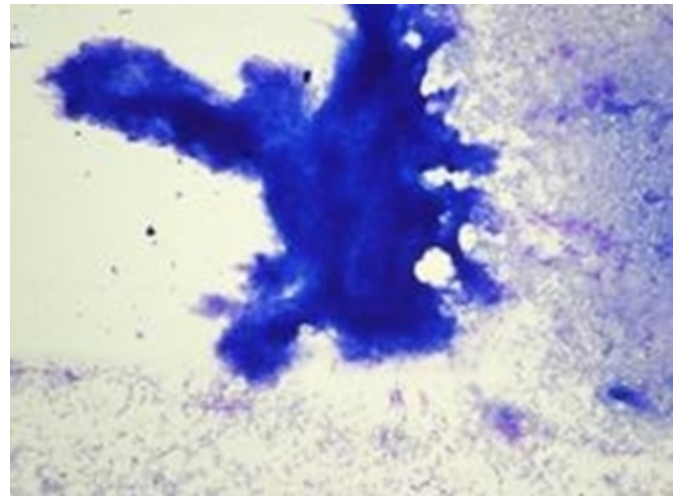
A 14 year-old girl presented with postnasal drip, and a 2 month history of enlarged left upper neck mass (4x3 cm). There was no fever or any other systemic symptom, and chest radiography was normal. Her blood chemistry was normal. Erythrocyte sedimentation ratio was 40mm/hour. Patient had no past history of tuberculosis. On endoscopic examination mucosal edema and hyperemia of the nasopharynx was observed. Purified protein derivative intradermal skin test was positive with 22 mm induration. The fine needle aspiration biopsy of the neck mass supported the diagnosis of a caseous granulomatous disease with central necrosis. Histopathological examination of the biopsy taken from posterior nasopharyngeal wall, and the mass excised from the neck revealed granulomatous inflammation with central necrotizing and caseating granulomas. On the basis of these findings the diagnosis considered as primary nasopharyngeal tuberculosis. For further treatment the patient was transferred to the Department of Infectious Diseases, and she started to take a 9 month antituberculosis therapy. Culture on Lowenstein-Jensen medium grew *Mycobacterium tuberculosis* at 6 weeks. On the third month of the medication, the nasopharyngeal mass was considerably reduced in size. After a 4 year follow-up there is no evidence of tuberculosis anywhere else in the body.

### CASE 2

A 20 year-old male came to our clinic with complaint of nasal obstruction, snoring and right neck lymphadenopathy (4x5cm). There was no systemic symptom, and chest radiography was clear. The blood chemistry was normal, but erythrocyte sedimentation ratio was elevated to 90mm/hour. Nasal endoscopy showed mucosal covered, pedunculated mass in the midline, filling the nasopharynx. Otoscopy demonstrated bilateral serous otitis media. The fine needle aspiration biopsy of the neck mass supported the diagnosis of a granulomatous disease (figure 1).

### Figure 1

Figure 1: FNAB

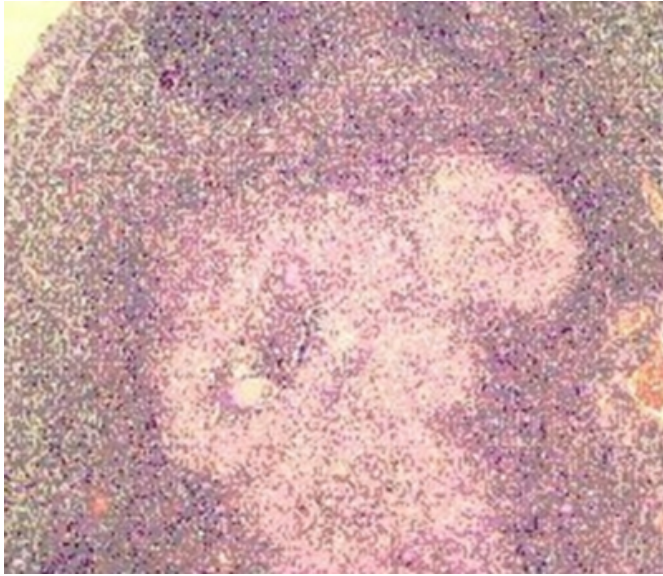


Necrotic tissue, lymphoid cells and many histiocytes are seen in cytopathologic examination of the fine needle aspiration biopsy material (Giemsa stain, 40X). These findings were reported as negative for malignancy, and consistent with granulomatous infection.

The histopathological findings of the mass curetted from the nasopharynx were reported to be consistent with the tuberculosis infection (figure 2). The patient was transferred to the Department of Infectious Diseases, and he began receiving a 4 drug antituberculosis regimen. Culture on Lowenstein-Jensen medium confirmed the presence of *Mycobacterium tuberculosis* 6 weeks later. At a 2-month follow-up examination the patient's nasal obstruction and serous otitis media were resolved. The neck mass was considerably reduced in size. After a 1,5 year follow-up the patient is still free of tuberculosis.

**Figure 2**

Figure 2: Microscopy



Histopathological examination of the slides stained with hematoxylin and eosine (100X) showed granulomas composed of epithelioid histiocytes and scattered Langhans giant cells at the periphery and caseation necrosis centrally. These granulomas were surrounded by a fibrous tissue with mature and some transformed lymphocytes.

**CASE 3**

A 53-year-old male patient came to us with a 3-month history of hoarseness, cough, odynophagia and 7-kg weight loss. There was painless, mobile neck mass with 1,5x2 cm size in the right jugulodigastric angle which had appeared 1 month ago. The patient had no history of tuberculosis, and was a heavy smoker of cigarettes (about 2 packs a day). Indirect laryngoscopy showed edematous epiglottis, ulcerated mass localized in the posterior commissure of vocal cords, thickening of right aryepiglottic fold, and pooling of saliva in the right piriform sinus. Vocal cords demonstrated normal mobility. With those findings malignancy was suspected, but further investigations disclosed the pre-diagnosis of malignancy and a granulomatous disease was being expected. Chest radiography demonstrated active cavitary pulmonary lesions. Erythrocyte sedimentation ratio was 80mm/hour, but other blood examinations were normal. A tuberculin skin test with an inoculation of 5 units of purified protein derived was positive with 20mm induration. The fine needle aspiration biopsy of the neck mass supported the diagnosis of a granulomatous disease. Multiple biopsies of the laryngeal lesion were carried out. Histopathologic examination

revealed the expected presence of a chronic granulomatous inflammation with giant cells and necrotic areas that suggested a tuberculous etiology. For further treatment the patient was transferred to the Department of Infectious Diseases, and then antituberculous medications were started. After 6 weeks the Lowenstein-Jensen culture grew significant amounts of *Mycobacterium tuberculosis* sensitive to the common chemotherapeutic agents. The patient's clinical picture gradually improved, and after a 3-year follow-up the patient is still free of laryngeal disease. There is no evidence of tuberculosis anywhere else in the body.

**DISCUSSION**

Today tuberculosis of the upper respiratory system is rarely seen because of the introduction of effective chemotherapy (2). Most of the reported cases in the past were secondary to pulmonary tuberculosis (2).

In the upper respiratory tract the nasopharynx is not a common site for tuberculosis (3). Nasopharyngeal tuberculosis can occur as the primary lesion without systemic or pulmonary disease, but primary nasopharyngeal tuberculosis, defined as an isolated tuberculosis infection of the nasopharynx in the absence of pulmonary or systemic tuberculosis, is an exceedingly rare entity (0.12% of all tuberculosis) (3). In a large historical review of more than 800 patients with pulmonary tuberculosis, nasopharyngeal involvement occurred in only 1.8 % of the patients (2). The majority of cases reported with nasopharyngeal tuberculosis have come from nations where tuberculosis is endemic (4).

The most common initial symptom is cervical adenopathy (70%) (5), and our patients with nasopharyngeal tuberculosis had cervical adenopathy as their presenting feature. The symptoms associated with nasopharyngeal tuberculosis include headache, sore throat, cough, tinnitus, hearing loss and postnasal discharge (6).

The differential diagnosis of this lesion includes nasopharyngeal carcinoma, Wegener's granulomatous, sarcoidosis, syphilis, leprosy, lymphoma and fungal infection. Harrison reported nasopharyngeal tuberculosis misdiagnosed as Wegener's granulomatous (7). It is well known that carcinoma of the nasopharynx itself can elicit granulomatous response in the peritumoral tissue. Chen reviewed 47 patients with granulomatous inflammation of the nasopharynx, and he found that 7 cases (15%) were actually nasopharyngeal carcinoma (8). Both of these studies emphasize the importance of careful clinic and pathologic

investigations.

The occurrence of tuberculosis in the oral cavity and in the larynx is variously documented in the literature (9, 10). A laryngeal localization is usually secondary to pulmonary tuberculosis, and occurs primarily in the posterior portion of the true vocal cords, the arytenoid cartilages and the false vocal cords. The posterior portion of the larynx is more prone to involvement as it lies in the direct line of mucocilliary tracheobronchial clearance. Clinically laryngeal involvement occurs in approximately 3% of cases of moderately advanced pulmonary tuberculosis (11). Kim et al reported this ratio between 15% and 37% (12).

The clinical pictures of laryngeal tuberculosis and carcinoma of the larynx are similar, and include hoarseness (80%-100% of cases), odynophagia (50%-67%), cough (44%-48%), stridor (25%), hemoptysis (18%-29%) and cervical lymphadenopathy (12%) (13, 14, 15). So it may sometimes be confused with laryngeal carcinoma because of this clinical similarity and macroscopic appearance. Review of literature showed us that it is sometimes really very difficult to differentiate laryngeal tuberculosis from malignancy. Bull reported 7 patients with laryngeal tuberculosis that mimicked carcinomas (16). Later Nedwicki described 2 patients presumed carcinoma of the larynx, but were found to have tuberculosis (17). Bobrov reported a case of misdiagnosed laryngeal tuberculosis (18), and Delap et al presented a case of laryngeal tuberculosis that clinically simulated laryngeal carcinoma (19). The other conditions in the differential diagnosis of laryngeal lesions are; syphilis, actinomycosis, rhinoscleroma, amyloidosis, and Wegener's granulomatous (20). It is important to confirm diagnosis of the lesion by histopathologic investigations to rule out associated carcinoma of the larynx and by microbiological and serological methods to rule out other granulomatous diseases where the treatment modality could differ vastly.

Special investigations may help to reveal diagnosis but are often unreliable. The least invasive investigation for diagnosis is tuberculin skin testing. The tuberculin skin test is usually positive in tuberculosis; however, a negative test result does not rule out the disease. In all our cases the tuberculin skin tests were highly positive. The erythrocyte sedimentation ratio may be elevated, as in all three cases described, and thus it is a good therapeutic indicator but is not specific. Confirmation of the diagnosis can be made with the following criteria :(1) compatible histopathologic appearance of biopsied tissue (granuloma with epitheloid

cells), (2) demonstration of AFB on biopsy specimen, and (3) growth of Mycobacterium Tuberculosis from the biopsy specimen (21, 22). However initial microbiologic investigation with conventional acid-fast stains (e.g., Ziehl-Neelsen) and the fluorochrome procedure with stains such as auramine can be unreliable and are negative in up to 50% of cases. Culture of mycobacteria is time consuming, requiring 5 to 6 weeks to produce results. The yield is also low. In the literature, cultures are reported to be positive in 50% to 70% of patients (23, 24). So the diagnosis is most often made by a combination of the clinical picture, histologic findings, and response to anti-tuberculous medication. The cases presented were diagnosed by clinical symptoms, histologic appearance, and their response to medication. The histopathologic features of caseous granuloma were positive in all patients. Finally the diagnosis's proved by grooving Mycobacterium Tuberculosis on Lowenstein- Jensen culture.

All patients were referred to our colleagues for further treatment in the infectious disease department. In our third case, tuberculosis was associated with pulmonary disease, but other cases were free of pulmonary tuberculosis. Treatment mainly consisted of a triple regimen of ethambutol, isoniazid and rifampin. Their response to medication were excellent. The follow-up period ranged from 1,5 years to 4 years.

### CONCLUSION

Tuberculosis must still be considered in the differential diagnosis for patients with laryngeal/nasopharyngeal masses. It can be easily confused with malignancy. The histopathologic investigation is the definitive test in differential diagnosis with carcinoma. The response of upper respiratory tract tuberculosis to antimycobacterial therapy is very good.

### References

1. Robbins SL, Cotran RS. Pathologic basis of disease. Philadelphia:WB Saunders Co. 1979:396-7.
2. Rohwedder JJ. Upper respiratory tract tuberculosis. Sixteen cases in a general hospital. *Ann Intern Med* 1974;80:708-13.
3. Martinson FD. Primary tuberculosis of the nasopharynx in a Nigerian. *J Laryngol Otol.* 1967;81:229-33.
4. Raizada RM, Behl R, Bhongade V, et al. Primary nasopharyngeal tuberculosis. *Ear Nose Throat J* 1984;63:171-4.
5. Waldron J, Van Hasselt CA, Skinner DW, et al: Tuberculosis of the nasopharynx: Clinicopathological features. *Clin Otolaryngol* 1992;17:57-9.
6. Pande TK, Hiran S, Rao VVB, et al: Primary lingual tuberculosis caused by *M. bovis* infection. *Oral Surg Oral Med Oral Pathol* 1995;80:172-4.
7. Harrison NK, Knight RK. Tuberculosis of the

nasopharynx misdiagnosed as Wegener's granulomatous. *Thorax* 1986;41:219-20.

8. Chen CL, Su JJ, Hsu MM, et al. Granulomatous nasopharyngeal carcinoma: with emphasis on difficulty in diagnosis and favorable outcome. *J Formos Med Assoc* 1991;90:353-6.

9. Eng HL, Lu S, Yang C: Oral tuberculosis. *Oral Surg Oral Med Oral Path* 1996;81:415-20.

10. Ordonez M, Orejas B, Gutierrez B: Tuberculosis orofaringea. A proposito de un caso en amigdala lingual. *Acta Otorrinolaringol Esp* 1999;50:575-8.

11. Ballenger JJ, Lea and Febiger: *Diseases of the Nose, Throat, Ear, Head and Neck*. 1985;486-9.

12. Kim MD, Kim DI, Yune HY, et al: CT findings of laryngeal tuberculosis: comparison to laryngeal carcinoma. *J Comput Assist Tomogr* 1997;21:29-34.

13. Ramadan HH, Tarazi AE, Baroudy FM: Laryngeal tuberculosis: Presentation of 16 cases and review of the literature. *J Otol* 1993;22:39-41.

14. Richter B, Kohler G, Milo F, et al: Epiglottic tuberculosis: Differential diagnosis and treatment. Case report and review of the literature. *Ann Otol Rhinol Laryngol* 2001;110:197-201.

15. Tu HY, Li HY, Huang TS: Laryngeal tuberculosis: a series of 46 patients. *Changeng Yi Xue Za Zhi*

1997;20:94-9.

16. Bull TR: Tuberculosis of the larynx. *Br Med J* 1966;2:991-2. 17. Nedwicki EG: Laryngeal tuberculosis simulating carcinoma of the larynx. *Med Times* 1970;98:181-7.

17. Bobrov VM: Tuberculous forms of epiglottitis. *Vestn Otorinolaringol* 1991;4:42-4. 19. Delap TG, Lavy JA, Alusi G, et al: Tuberculosis presenting as a laryngeal tumour. *J Infect* 1997;34:139-41.

18. Pillsbury HC 3rd, Sasaki CT: Granulomatous diseases of the larynx. *Otolaryngol Clin North Am* 1982;15(3):539-51.

19. Cantrell RW, Jensen JH, Reid D. Diagnosis and management of tuberculous cervical adenitis. *Arch Otolaryngol* 1975;101:53-57.

20. Kanlikama M, Mumbuc S, Bayazit Y, et al. Management strategy of mycobacterial cervical lymphadenitis. *J Laryngol Otol* 2000;114:274-278.

21. Sloane MF. Mycobacterial Lymphadenitis. In: Rom WN, Garay SM, eds. *Tuberculosis*. Boston/New York/Toronto/London: Little, Brown and Company; 1996. p. 577-83.

22. Ibekwe AO, al Shareef Z, al Kindy S. Diagnostic problems of tuberculous cervical adenitis (scrofula). *Am J Otolaryngol* 1997;18:202-5.

**Author Information**

**Ebru Tas, M.D.**

ROTA KBB ORL Clinic

**Ethem Sahin, M.D.**

Maltepe University ORL Department

**Sukran Vural, M.D.**

Bakirkoy Dr. Sadi Konuk Education and Research Hospital ORL Department

**H. Kemal Turkoz, M.D.**

Okmeydani Education and Research Hospital, Pathology Department

**A. Okan Gursel**

Assistant Professor, Clinical Director of ORL Department, Fatih Sultan Mehmet Education and Research Hospital